

Pregnancy with Intrauterine Device Perforation: A Case Report

Shamsi Zare, M.D.¹, Rozbeh Sohrabi, M.D.², Hana Sohrabi, M.Sc.^{3*} 

1. Department of Obstetrics and Gynaecology, Faculty of Medicine, Kurdistan University of Medical Sciences, Sanandaj, Iran
2. Students' Research Committee, Faculty of Medicine, Kurdistan University of Medical Sciences, Sanandaj, Iran
3. Students' Research Committee, Faculty of Nursing and Midwifery, Kurdistan University of Medical Sciences, Sanandaj, Iran

Abstract

Although intrauterine devices (IUDs) are known for their low failure rate in pregnancy prevention, potential risks associated with their use include uterine perforation and migration through the abdomen. In this particular case, the patient experienced simultaneous IUD failure and perforation, with the device becoming embedded in an omentum. A 28-year-old woman who was 39 weeks plus one day gestation presented for caesarean section. During the caesarean section, it was discovered that the IUD had entered the omentum through a hole in the posterior part of the uterus. The result of the birth was a live boy. IUD perforation is most commonly observed during the insertion procedure; however, it may rarely occur at a later stage. IUD perforations are frequently asymptomatic and remain undetected until follow-up assessments are conducted or clinical manifestations become apparent. The presence of gastrointestinal symptoms is commonly observed in cases with intraperitoneal migration of the IUD. Although the occurrence of abdominal pain, diarrhoea, and fever with a missing IUD are indicative, they may not always be present. Nonspecific signs and symptoms lead to misdiagnosis and the consequent delay in initiating appropriate treatment. In the present case, the co-occurrence of IUD embedded in the omentum and pregnancy posed a challenge due to the device's rapid and imprecise shift, which complicated its accurate localisation. In such scenarios, ultrasonographic guidance can serve as a valuable tool to enhance accuracy and decrease adverse outcomes.

Keywords: Intrauterine Device, Omentum, Uterine Rupture

Citation: Zare Sh, Sohrabi R, Sohrabi H. Pregnancy with intrauterine device perforation: a case report. Int J Fertil Steril. 2024; 17(1): 91-93. doi: 10.22074/IJFS.2023.1974526.1402
This open-access article has been published under the terms of the Creative Commons Attribution Non-Commercial 3.0 (CC BY-NC 3.0).

Introduction

Intrauterine devices (IUDs) are one of the most frequently used contraceptive methods. Severe and rare complications include uterine perforation and displacement into the abdomen (1). There have been reports of intra-abdominal IUDs that caused abdominal wall embedment, bowel injury, fistula formation, and bladder perforation. The rate of uterine perforation is 0.4 to 2.2 out of 1000 copper IUD insertions (2). IUD failures can result in preterm labour and miscarriage. Additionally, uterine perforation can result from the inserter, or the uterus (3). Pregnancy and reaching term despite rupture of the uterus are rare (4). It is the aim of this study to describe a rare case of pregnancy with IUD perforation and embedment within the omentum found during a caesarean section.

Case report

A 28-year-old woman, [gravida (G), para (P), live child (Lch), dead child (Dc), abortion (Ab)] G4 P2 Lch1 Dch1Ab 1 presented to the Ba'ath Hospital in Sanandaj, Iran, on May 24, 2022 at 39 weeks plus one day gestation

for a caesarean section because of her history of two previous caesarean sections. She reported a copper IUD (TCu380A) placement nine months prior to presentation, which had not been removed or expelled. Her primary care physician performed a physical examination and history during the first visit, and they were unremarkable. As far as the IUD was concerned, she was completely symptom-free. She was sexually active and had not conceived. She did not suffer from abdominal or pelvic pain.

In the nine months following insertion, a follow-up examination revealed that the patient was pregnant. She was scanned with ultrasonography and a live embryo was spotted with cardiac activity. The average gestational age according to FL/AC/HC, BPD was 16 weeks+2 days (\pm 2 weeks). The foetus weighed 143 grams. The amount of amniotic fluid was within normal limits, and the placenta was located in the fundus of the uterus with a normal relationship to the internal cervical os. An IUD was seen in the lower posterior uterine segment that penetrated the myometrium, but not the serosa, and there were no signs of uterine rupture. During the caesarean section, a hole was seen in the posterior region of the uterus through which the IUD had entered the omentum (Fig.1). This hole might

Received: 27/November/2022, Revised: 30/March/2023, Accepted: 25/June/2023
*Corresponding Address: P.O.Box: 6617958777, Students' Research Committee, Faculty of Nursing and Midwifery, Kurdistan University of Medical Sciences, Sanandaj, Iran
Email: Hana.Sohrabi@Muk.ac.ir



have been caused by an IUD because, except for caesarean section, her only history was manipulation of the uterus. The birth resulted in an apparently healthy, live baby boy who weighed 3500 g [A1] and had an Apgar score of 9.10. An operation was performed to repair the posterior hole in the uterus. The patient and the baby were discharged in good general condition three days after surgery.

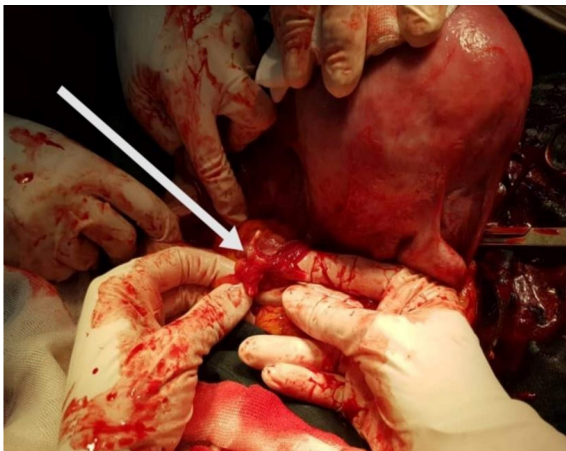


Fig.1: Intrauterine device (IUD) in a part of the omentum (white arrow).

According to our institutional policies, this Case Report required patient consent to participate which has been filed in the patient chart for our records. At Kurdistan University of Medical Sciences, Sanandaj, Iran approved this case study (IR.MUK.REC.1401.247).

Discussion

IUDs are one of the most commonly used long-acting contraceptives worldwide (5). Despite the fact that IUDs are highly effective, they may not work all the time. There are very few instances of IUDs that perforate the uterus (3). However, significant harm associated with perforation may be the loss of the contraceptive effect, which results in unplanned and often unwanted pregnancies (6). The migration of a perforated IUD can occur to various sites within the pelvis, such as adhesions, the omentum, the pouch of Douglas, or it may adhere to the colon sigmoid (7).

The majority of perforations occur during the insertion of an IUD, although they can occur later. Often these perforations remain unnoticed until follow-up examinations are performed or they become symptomatic. Missing IUDs can sometimes cause gastrointestinal symptoms, especially when the device migrates intraperitoneally. A combination of abdominal pain, diarrhoea, and fever may be indicative, but not always present (8). Misdiagnosis and delay in treatment is attributed to nonspecific signs and symptoms (9). The patient in this case complained of a four months history of amenorrhoea. A vaginal examination was performed and the IUD strings were not observed. A beta human chorionic gonadotropin (hCG) test was positive and she underwent a vaginal ultrasonography. The ultrasonography showed a

single alive intrauterine foetus with normal movements, an average gestational age according to FL/AC/HC, BPD of 16 weeks+2 days (± 2 weeks). The IUD was seen in the posterior lower uterine segment with penetration into the myometrium but not through the serosa. IUD migration is most commonly associated with “missing strings” (8).

Failure to visualize or feel strings on examination should not be interpreted as an indication that the IUD has been expelled through the cervix or vagina. It is vital to proceed with ultrasound in this scenario (7). If ultrasonography does not detect the IUD within the uterus, an x-ray of the pelvis and abdomen should be obtained to determine if the IUD is in the peritoneal cavity. If both an ultrasound and a pelvic and abdominal x-ray do not detect the IUD, the IUD was probably expelled from the patient (10). Due to the patient's pregnancy, the only modality that could be used was ultrasonography. During surgery, the device was barely visible and cloaked in the omentum. Furthermore, there was a hole in the posterior part of the uterus. There is a low incidence of rupture of the posterior wall of the uterus. This rupture may be covered by the intestinal loop or omentum, which makes some of the minor symptoms difficult to detect (9). Both the patient and the newborn were fortunate to have a favourable outcome. The occurrence of pregnancy and the continuation of pregnancy until term with uterine rupture is rare, but it can have severe consequences (4).

Conclusion

This case highlights the potential risks associated with IUD use, particularly perforation and migration. While these complications may be rare, they can lead to significant morbidity and require prompt management, particularly in cases where the patient is asymptomatic. It is imperative that healthcare providers remain vigilant and promptly investigate any signs or symptoms that suggest an IUD-related complication to ensure optimal patient care. The use of ultrasound in IUD-related complications should be further encouraged to improve patient outcomes.

Acknowledgements

We express our appreciation to the patient and staff who assisted us. There is no financial support and conflict of interest in this study.

Authors' Contributions

Sh.Z.; Investigation, Conceptualization, Methodology, and Data curation. H.S.; Data curation, Writing of the original draft preparation, and Supervision. R.S.; Writing - reviewing and editing, and Validation. All authors read and approved the final manuscript.

References

1. FaridMojtahedi M, Khezri A. Cecum perforation following intrauterine device insertion: a case report. *IJOGI*. 2022; 24(12): 132-136.
2. Gao T, Lacue A, Brandi K. Intra-abdominal IUD requiring bowel resection in pregnancy. *J Minim Invasive Gynecol*. 2021; 28(11): 1812-1813.

3. Tarafdari A, Malek M, Pahlevan Falahy E, Hadizadeh A. IUD perforation and embedment within omentum: A rare and perplexing incidence. *Clin Case Rep.* 2022; 10(4): e05732.
 4. Sohrabi H, Yousefi Sharmi SR. Pregnancy with uterine perforation: a case report. *Sci J Kurdistan Univ Med Sci.* 2021; 25(6): 127-132.
 5. Gündüz R, Ağaçayak E, Akkılıç Dönmez D, Findik FM, Evsen MS, Gül T. Evaluation of patients with uterine perforation after intrauterine device placement and determination of risk factors: a retrospective case-control study. *Eastern J Med.* 2022; 27(2): 264-271.
 6. Rowlands S, Oloto E, Horwell DH. Intrauterine devices and risk of uterine perforation: current perspectives. *Open Access J Contracept.* 2016; 7: 19-32.
 7. Carroll A, Paradise C, Schuemann K, Schellhammer SS, Carlan SJ. Far migration of an intrauterine contraceptive device from the uterus to the small bowel. *Clin Case Rep.* 2022; 10(3): e05589.
 8. Rahnemai-Azar AA, Apfel T, Naghshizadian R, Cosgrove JM, Farkas DT. Laparoscopic removal of migrated intrauterine device embedded in intestine. *JLS.* 2014; 18(3): e2014.00122.
 9. Chen SH, Du XP. Silent spontaneous posterior uterine rupture of a prior caesarean delivery at 36 weeks of gestation. *BMC Pregnancy Childbirth.* 2019; 19(1): 23.
 10. Robert L, Barbieri M. How common is IUD perforation, expulsion, and malposition? *OBG Management* 2020; 34(4): 8-22.
-