

Office Hysteroscopy in Patients with Abnormal Uterine Bleeding and Normal Transvaginal Sonography

Mojgan Barati, M.D.^{1*}, Sara Masihi, M.D.², Farideh Moramezi, M.D.²,
Shabnam Salemi, M.D.¹

1. Obstetric and Gynecology Department, Imam Khomayni Hospital, Ahwaz, Iran

2. Obstetric and Gynecology Department, Razi Hospital, Ahwaz, Iran

Abstract

Background: Abnormal uterine bleeding (AUB) is one of the most common clinical problems in gynecology. Transvaginal sonography (TVS) and hysteroscopy are two diagnostic methods for patients with AUB. For most of the patients with AUB, diagnostic hysteroscopy can be done in clinic with minimal discomfort and much lower expense than operative room.

Materials and Methods: In our clinical trial study, from March 21, 2005 to March 20, 2007, patients with AUB in Ahwaz Imam Khomayni hospital, after history and physical examinations underwent TVS. Of those, 147 patients with normal TVS entered the study and were considered for outpatient hysteroscopy. Patients with endometrial cavity lesion were scheduled for operation room, and those with empty endometrial cavity aspiration biopsy were done outpatiently. Specimens were sent to pathologist for examination.

Results: All the patients were divided into three groups: group 1 or minority was under 30 years old (7 women), group 2 was 30-40 years, and group 3 or majority was over 40 years old (96 women). 115 patients (78.2%) had normal and 32 patients (21.8%) had abnormal hysteroscopic results. 116 patients (78.8%) had normal and 31 patients (21.2%) had abnormal pathologic results; moreover, cervical canal polyp was the most common lesion hysteroscopically and pathologically in all groups.

Conclusion: Of 147 patients (100%) with AUB and normal TVS, 32 patients (21.8%) were abnormal hysteroscopically. Cervical canal polyps may be missed by transvaginal sonography, but can be diagnosed by hysteroscopy. In patients with AUB and normal TVS, hysteroscopy can be used as the second step.

Keywords: Abnormal Uterine Bleeding, Transvaginal Sonography, Hysteroscopy

Introduction

Abnormal uterine bleeding is one of the most common clinical problems in gynecology (1). Transvaginal sonography and hysteroscopy are among diagnostic methods in women with abnormal uterine bleeding (1,2). One of the advantages of transvaginal sonography is detection of uterine (leiomyomata, endometrial polyps, and adenomyosis) and ovarian lesions (ovarian tumors) (1). Data gathered by hysteroscopy is more informative than blind sampling (3-9), which in this regard the diagnosis of endometrial polyps or leiomyoma can be mentioned (6, 7, 9, 10). For many patients, diagnostic hysteroscopy can be done outpatiently with minimal discomfort and less expenses than the operation room (11).

The aim of this study is to determine the patients suffering from abnormal uterine bleeding with normal transvaginal sonography, need also to have hysteroscopy or content to normal transvaginal sonography.

Materials and Methods

This clinical trial study was carried out in Imam Khomayni Hospital in Ahwas during March 21, 2005 to March 20, 2007. In this period of time, all patients who entered the hospital for abnormal uterine bleeding, after history and clinical examinations, underwent transvaginal sonography. Among them, 147 patients with normal transvaginal sonography (with endometrium less than 5mm thickness in post menopausal group and less than 12mm thickness in childbearing group, with no endometrial lesion) were entered the study and underwent outpatient hysteroscopy. If there was any lesion in endometrial cavity during office hysteroscopy, the patient would be scheduled for operation to extract the lesion by operative hysteroscopy. If there was no endometrial lesion, aspiration biopsy would be carried out outpatiently. The samples from all patients were sent for pathological examinations. In this study the patients

* Corresponding Address: P.O.Box: 6193673166, Obstetric and Gynecology Department, Imam Khomayni Hospital, Ahwaz, Iran
Email: brati_m@yahoo.com



were divided into 3 age groups: group 1: below 30 years old, Group 2: 30-40 and group 3: over 40 years old. Data from patients' histories, clinical examinations, transvaginal sonographic, and hysteroscopic and pathologic results were gathered and analyzed by SPSS 13 software. For analyzing, statistical description methods such as distribution frequency tables and calculation values for sensitivity, specificity and predictive value were used

Results

Hysteroscopic results for different age groups are shown in table 1. Table 1 shows that the majority of the patients (96 women) are in group 3 and the minority of patients (7 women) are in group 1. Table 2 shows 115 patients (78.2%) have normal hysteroscopy and 32 patients (21.8%) have abnormal hysteroscopy and the most common lesion is cervical canal polyp. Two cervical canal polyps are shown in figure 1. According to pathologic findings, 116 patients (78.8%) are normal and 31(21.2%) are abnormal and the most common lesion is cervical canal polyp.

Table 1: Hysteroscopy in different age groups

Age group (year)	Hysteroscopy		Total
	Normal	Abnormal	
30>	4(2.7%)	3(2.1%)	7(4.8%)
30-40	31(21.1%)	13(8.8%)	44(29.9%)
>40	80(54.4%)	16(10.9%)	96(65.3%)
Total	115(78.2%)	32(21.8%)	147(100%)

Table 2: Hysteroscopic and pathologic results

Report	Hysteroscopy	Report	Pathology
Normal	115 (78.2%)	Normal	116(78.8%)
Abnormal	32 (21.8%)	Abnormal	31(21.2%)
Cervical canal polyp	12 (8.2%)	Cervical canal polyp	12(8.2%)
Endometrial polyp	10 (6.8%)	Endometrial polyp	11(7.5%)
Endometrial irregularity (probable hyperplasia)	6 (4.1%)	Endometrial hyperplasia	6(4.1%)
Endometrial atrophy	3 (2%)	Endometrial atrophy	2(1.4%)
Submucosal myoma	1 (0.7%)	Submucosal myoma	0(0%)

Table 3: Relationship between hysteroscopy and pathology

Diagnostic methods		Pathology		Total
		Normal	Abnormal	
Hysteroscopy	Normal	114(77.5%)	1(0.7%)	115(78.2%)
	Abnormal	2(1.4%)	30(20.4%)	32(21.8%)
Total		116(78.9%)	31(21.1%)	147(100%)

According to table 3, of 115 patients (78.2%) with normal hysteroscopy, one patient (0.7%) is abnormal pathologically (endometrial polyp). Also among 32 patients (21.8%) with abnormal hysteroscopy, 2 patients (1.4%) are normal pathologically (by hysteroscopy, one person is reported to have endometrial atrophy and one person submucosal myoma). Comparison of hysteroscopic and pathologic results show hysteroscopy has 97.8% sensitivity with confidence interval of 95% (84.9-99.7), specificity of 99% with confidence interval of 95% (92-99.5), and 94% positive predictive value and 99% negative predictive value. Negative predictive value of transvaginal sonography is 78.9%. These findings show high conformity between hysteroscopy and pathology.

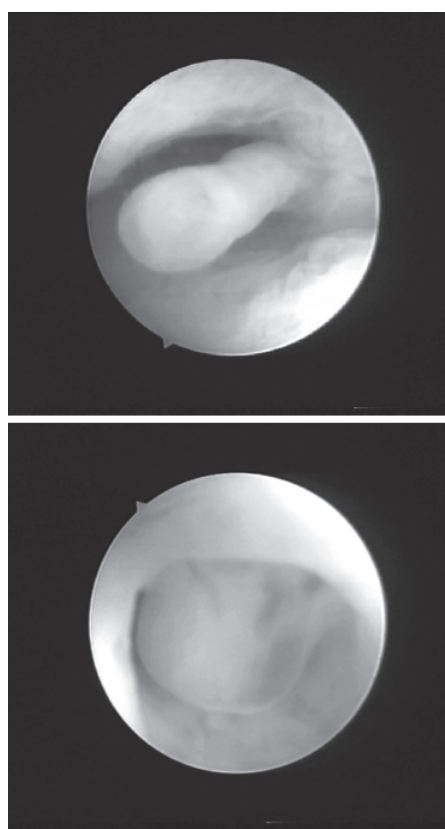


Fig 1: Cervical canal polyp in hysteroscopy

Discussion

Traditionally, endometrial biopsy (often in operation room) has been done routinely in the management of patients with persistent abnormal uterine bleeding and normal transvaginal sonography to rule out malignancy. This study was shown that these patients could have outpatient hysteroscopy and outpatient endometrial biopsy, and also 21% of lesions which were missed by normal transvaginal sonography alone, were detected by hysteroscopy.

Of 147 patients (100%) with normal transvaginal sonography, 32 patients (21.8%) were abnormal and 115 patients (78.2%) were normal hysteroscopically

(Table 2). Of these 115 patients with normal hysteroscopy, 114 patients were confirmed normal by pathology, which showed 99% negative predictive value. One remained normal hysteroscopy had endometrial polyp pathologically. Also, table two showed 10 patients were diagnosed to have endometrial polyp by hysteroscopy, and 11 patients were diagnosed to have endometrial polyp pathologically. In some cases, endometrial polyps were not showed clearly by hysteroscopy, but they could be diagnosed pathologically. This difference could be due to this point.

Of 32 patients with abnormal hysteroscopy, 30 patients were confirmed abnormal by pathology which showed 94% positive predictive value. Two patients with abnormal hysteroscopy had normal pathology: one with submucosal myoma and the other one with endometrial atrophy. Three patients were diagnosed to have endometrial atrophy by hysteroscopy, whereas 2 patients had the same diagnosis pathologically. Hysteroscopy doesn't have high accuracy in diagnosis of diffuse endometrial lesions. One patient was diagnosed submucosal myoma by hysteroscopy, but it was reported normal pathologically.

Cervical canal polyp was the most common lesion and the number of patients who were diagnosed to have cervical canal polyp by hysteroscopy and pathology were equal (12 patients) which was an indicator of high conformity of hysteroscopy and pathology. Six patients had irregular endometrium by hysteroscopy which suggested probable endometrial hyperplasia. The results of pathology came out the same for the above mentioned-patients. These values indicate high conformity between hysteroscopy and pathology in this study. Regarding to high conformity between hysteroscopy and pathology in this study (Table 3), it was showed that diagnostic ability of transvaginal sonography was less than hysteroscopy. Also of 115 patients (78.2%) who had normal hysteroscopic results, only one patient (0.7%) had abnormal pathologic result; and of 32 patients (21.8%) who had abnormal hysteroscopic results, 2 patients (1.4%) had normal pathologic results. This is another indicator of high level of accuracy of hysteroscopy in this study.

The majority of the patients were over 40 years old (group 3) because abnormal uterine bleeding is a common problem in this age group.

In one study, sensitivity and specificity of hysteroscopy were 100% and 84%, respectively; which agrees with our results (12). In another study carried out in UK, 400 patients with abnormal uterine bleeding were investigated. For the first step, transvaginal sonography and endometrial biopsy, and as the second step, hysteroscopy were recommended (13) which agrees with the current study. In another study in Italy, 419 patients with abnormal uterine bleeding were considered. It again demonstrated that transvaginal sonography was a suitable diagnostic method for the first step, but hysteroscopy was more accurate than transvaginal sonography

(14).

In another study in Turkey, for diagnosis of intra uterine lesions in patients with or without abnormal uterine bleeding; transvaginal sonography and hysteroscopy were carried out. Sensitivity and specificity of transvaginal sonography were 56.3% and 100%, respectively. Also, hysteroscopy had 81.3% sensitivity and 100% specificity (15).

Conclusion

Overall, it can be stated that from 147 patients (100%) whose transvaginal sonography were normal, 32 patients (21.8%) were reported to have abnormal hysteroscopy. According to our study, it is clear that cervical canal polyps are missed in transvaginal sonography. Therefore, hysteroscopy is one of the best methods to detect the polyps for this area. According to high conformity between the hysteroscopy and pathology, diagnostic ability of hysteroscopy was higher than transvaginal sonography. Therefore, it is recommended that patient with abnormal uterine bleeding whose transvaginal sonography is normal, hysteroscopy is considered to be as the second step.

Acknowledgment

The authors of this article wish to express their appreciations to Dr. Mehran Varshochi, general practitioner; Mr. Cheragian, statistics advisor; Ms Eskandari, typist; and the dedicated staff of emergency and gynecology departments of Imam Khomayni hospital who assisted us in this research.

References

1. Robert L. Barbieri, Kenneth J. Ryan. The menstrual cycle. Kenneth J. Ryan. *Kistner's Gynecology & Women's Health*. 7th ed, USA, Mosby, 1999; 48-52
2. Dysfunctional uterine bleeding. Leon S, Marc A. *Clinical gynecologic endocrinology and infertility*. 7th ed, Philadelphia, USA, Lippincott Williams & Wilkins, 2005; 555-557
3. Goldrath MH, Sherman AI. Office hysteroscopy and suction curettage: can we eliminate the hospital diagnostic dilatation and curettage? *Am J Obstet Gynecol* 1985; 152(2): 220-229
4. Gimpelson RJ. Office hysteroscopy. *Clin Obstet Gynecol* 1992; 35(2): 270-281
5. Itzkowic DJ, Laverty CR. Office hysteroscopy and curettage-a safe diagnostic procedure. *Aust N Z J Obstet Gynaecol* 1990; 30(2): 150-153
6. Gimpelson RJ, Rappold HO. A comparative study between panoramic hysteroscopy with directed biopsies and dilatation and curettage: a review of 276 cases. *Am J Obstet Gynecol* 1988; 158(3 pt 1): 489-492
7. Loffer FD. Hysteroscopy with selective endometrial sampling compared with D&C for abnormal uterine bleeding: the value of a negative hysteroscopic view. *Obstet Gynecol* 1989; 73(1): 16-20
8. Iossa A, Cianferoni L, Ciatto S. Hysteroscopy and endometrial cancer diagnosis: a review of 2007 consecutive examinations in self-referred patients. *Tumori* 1991; 77(6): 479-483
9. Crescini C, Artuso A, Repetti F. Hysteroscopic diagnosis in patients with abnormal uterine hemorrhage and previous endometrial curettage. *Minerva Ginecol* 1992; 44(5): 233-235
10. Brooks PG, Serden SP. Hysteroscopic findings after un-

successful dilatation and curettage for abnormal uterine bleeding. *Am J Obstet Gynecol* 1988; 158(6 pt 1): 1354-1357

11. Malcolm G. Munro, Andrew I. Brill, William H. Parker. *Gynecologic endoscopy*. Jonathan S. Berek. Berek & Novak's Gynecology. 14th ed, Philadelphia, USA, Lippincott Williams & Wilkins, 2007; 787-789

12. Epstein E, Ramirez A, Skoog L. Transvaginal sonography, saline contrast sonohysterography and hysteroscopy for the investigation of women with postmenopausal bleeding and endometrium >5mm. *Ultrasound Obstet Gynecol*. 2001; 18(2): 157-162

13. Tahir MM, Bigrigg MA, Browning JJ. A randomised control-

led trial comparing transvaginal ultrasound, outpatient hysteroscopy and endometrial biopsy with inpatient hysteroscopy and curettage. *Br J Obstet Gynaecol*. 1999; 106(12): 1259-1264

14. Garuti G, Sambruni I, Cellani F. Hysteroscopy and transvaginal ultrasonography in postmenopausal women with uterine bleeding. *Int J Gynaecol Obstet*. 1999; 65(1): 25-33

15. Kelekci S, Kaya E, Alan M. Comparison of transvaginal sonography, saline infusion sonography, and office hysteroscopy in reproductive-aged women with or without abnormal uterine bleeding. *Fertil Steril*. 2005; 84(3): 682-686
