

## Hysteroscopic Subendometrial Embryo Delivery (SEED), Mechanical Embryo Implantation

Michael Kamrava, M.D.\*, Mei Yin, M.Sc.

West Coast IVF Clinic, Inc., Beverly Hills, California, USA

### Abstract

**Background:** A major hurdle to improved *in vitro* fertilization (IVF) success rate is defective endometrial receptivity and implantation. Various techniques have been advocated to increase implantation while reducing side effects. Currently, embryo transfer (ET) is performed blindly without direct visualization. As such, we sought to develop a technique utilizing a flexible mini-hysteroscope with a flexible catheter for direct implantation of the blastocyst(s).

**Materials and Methods:** This was a case study performed at West Coast IVF Clinic, Inc., Beverly Hills, California 90212. A total of 15 IVF Cycles in 13 patients (average age = 29) underwent visually directed ET and endometrial implantation. All women received luteal support.

The main outcome measure in this study, both clinically and procedurally, was the relevant development and assessment of a novel surgical technology.

**Results:** In this study, eight (60%) pregnancies ensued [5 (62.5%) clinical and 3 (37.5%) biochemical]. Of note, there was no uterine scratching, uterine bleeding, or ectopic pregnancies. Significantly, high-order pregnancies were decreased; only one twin was conceived.

**Conclusion:** Preliminary data suggest mechanically assisting implantation with a hysteroscopic blastocyst ET (SEED) offers a viable option for improving pregnancy outcome.

**Keywords:** Endometrium, ART, *In vitro* Fertilization, SEED

### Introduction

After two decades of clinical practice, the take home pregnancy rate hovers around 38% for women under 35 years of age and decreases to less than 15% for women 41-42 years of age (1). Considering that the 'normal' pregnancy rate has been theorized to approximately 10-15%, this low "take home baby rate" is a reflection of biological, genetic, morphological, and endocrine inaccuracies associated with the system in question. In patients undergoing *in vitro* fertilization (IVF) procedures one major set of hurdles, which often prevents healthy embryos from becoming pregnancies, are problems associated with endometrial receptivity and implantation (2-5). From a clinical practice perspective in our new age of pre-implantation diagnosis, the embryo transfer process may now be regarded as a rate-limiting factor.

Various techniques for embryo transfer (ET) have been advocated to increase pregnancy rates while reducing side effects from the procedure, such as lost embryos and ectopic pregnancies (6, 7). In addition, the advantages of different catheters have been debated (8-10). These methods, however, use

a "blind" technique of catheter introduction into the uterus. Thus since the embryo, having the zona pellucida at time of transfer, would still be floating in the uterine cavity between one to three days from the time of transfer, the problems of "lost embryos" and the occurrence of ectopic pregnancies persist. We have hypothesized that the mechanical insertion of the blastocyst into the endometrium under direct visualization would increase the implantation and clinical pregnancy rate of IVF. The aim of this study was to re-investigate the potential of sub-endothelial ET, a procedure which originated from early mouse experiments (11) and in humans in the mid to late 1990's (12, 13) via trans-abdominal approaches. In contrast to these earlier investigations we propose to use hysteroscopy to direct and effect the implantation procedure.

### Materials and Methods

#### Patients

The study was approved by local IRB at West Coast IVF Clinic, Inc. There were 13 patients under the age of 35 years, who had 15 consecutive IVF cycles in this study. Controlled ovarian hyperstimu-



lation was initiated with follitropin  $\beta$  (Follistim®, Organon Pharmaceuticals, Inc.). Endogenous gonadotropins [the prevention of a luteinizing hormone (LH) surge] were controlled with ganirelix acetate (Antagon™, Organon Pharmaceuticals, Inc.). Oocyte retrieval was carried out in an office setting under local anesthesia and mild sedation. Embryo culturing was performed using sequential media (G1 and G2; Vitrolife) to day five. Up to two fully expanded hatching grade 1 blastocysts were transferred (Fig 1A). Luteal phase support was provided (3000 IU of hCG at three and six days post retrieval; Fig 1B, C). Serum human chorionic gonadotropin (hCG) was quantified at ten days following the last hCG administration. A concentration of 5 IU/ml with increased range over two days and delayed menses were used as confirmations of pregnancy. Informed consent was obtained prior to the start of the cycle.

#### **Description of hysteroscopic implantation**

A lightweight flexible mini- hysteroscope (Storz™) was used for visualization of the endometrial cavity (Fig 1D). The scope incorporates a flexible distal end of 3mm in diameter with a straight through operating channel. In addition, the optic filter is directly connected to a light source, decreasing the weight of the scope. Nitrogen gas instead of CO<sub>2</sub> is used for uterine distention. Nitrogen gas is inert and is used in the trimixture of Nitrogen, Oxygen and

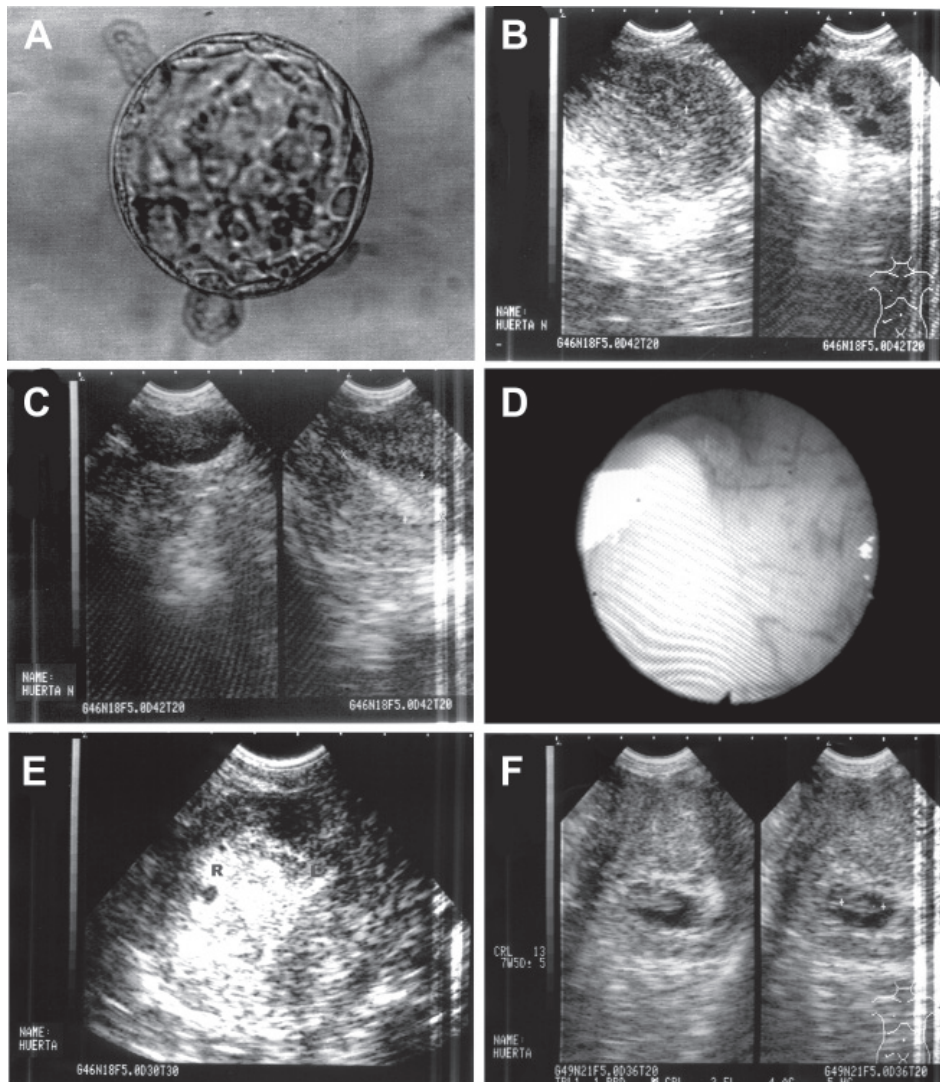
Carbon Dioxide utilized for embryo culture in an IVF laboratory. Gas pressure is set at max 70 mm mercury (HG). A maximum of 50 cc of gas is used during the entire procedure. The transfer catheter is polycarbonate based with a tapered tip (to 500  $\mu$ m), beveled to 45-60° (Precision Reproduction, LLC Los Angeles, CA 90212 USA). The catheter is inserted to a distance of 0.5cm horizontally and to a depth of approximately 1mm into the endometrium. The embryo is deposited under direct hysteroscopic visualization (Fig 1D).

#### **Results**

In this study, 15 IVF cycles in 13 patients were completed. A total of 11 cycles involved the use of intra-cytoplasmic sperm injection (ICSI) due to male factor problems. Endometrial thicknesses varied between 7 and 16mm by transvaginal ultrasound. There were eight positive  $\beta$ hCGs at levels greater than 5IU/ml eleven days after embryo implantation. There were five clinical pregnancies as evidenced by the presence of a gestational sac (Fig 1E) visualized by ultrasound examination at five weeks of gestation and heart beat at six weeks of gestation (Fig 1F). A total of 3 first trimester spontaneous abortions occurred at seven to eight weeks of gestation. Healthy term babies were delivered by two patients; of which one of these patients had a spontaneous abortion in a previous implantation. No ectopic pregnancies were seen (Table 1).

**Table 1: Clinical data of subendothelial ET (transcervical).**

<b>Diagnosis</b>	<b>Age</b>	<b>Weight (lbs)</b>	<b>Gravida</b>	<b>Para</b>	<b>Sab</b>	<b>Ectopic</b>	<b>Endometrial thickness (mm)</b>	<b>Pregnancy outcome</b>
<b>Tubal disease</b>	31	200	1	0	0	1	9	Negative
<b>Tubal disease</b>	31	200	1	0	0	1	8	Negative
<b>Idiopathic</b>	33	130	0	0	0	0	9	Negative
<b>Endometriosis/ Male factor</b>	31	172	1	0	1	0	10	Biochemical
<b>Male factor</b>	31	130	0	0	0	0	13	Spont. Ab
<b>Ovulatory dysfunction/ Male factor</b>	34	170	1	0	1	0	9	Biochemical
<b>Male factor</b>	33	202	0	0	0	0	10	Negative
<b>Idiopathic</b>	34	136	3	0	3	0	13	Negative
<b>Male factor</b>	31	130	0	0	0	0	12	Negative
<b>Tubal factor</b>	28	254	3	3	0	0	16	Negative
<b>Ovulatory dysfunction</b>	26	150	0	0	0	0	9	Spont. Ab
<b>Male factor</b>	34	130	0	0	0	0	7	Spont. Ab
<b>Ovulatory dysfunction/ Male factor</b>	31	224	2	0	2	0	7	Biochemical
<b>Ovulatory dysfunction</b>	26	150	0	0	0	0	10	Term preg
<b>Ovulatory dysfunction</b>	29	133	0	0	0	0	11	Term preg



**Fig 1: Stages of subendometrial embryo transfer. Expanded hatching blastocyst (A); estrogenic endometrium (B); progesterone endometrium (C); subendometrial embryo transfer (D); early gestational sac at 5 weeks (E); fetus at 6 weeks (F).**

## Discussion

Various techniques and technologies for ET have been proposed since the introduction of IVF. This list includes ultrasound-controlled transcervical intrauterine transfer or transmyometrial transfer and more invasive procedures, often referred to as surgical ET, which include: gamete intra-fallopian transfer (GIFT), zygote intra-fallopian transfer (ZIFT), pronuclear stage transfer and embryo intra-fallopian transfer (EIFT) (14-17). Although ultrasound guided ET was desired to improve successful pregnancy outcomes and reduce side effects, it has been received with mixed results (18-32). It also requires simultaneous coordination of two professionals, the physician performing the transfer and the ultrasonographer (29). Furthermore,

all transcervical and transmyometrial techniques involve “blind” introduction of the embryo(s) via transfer catheters with no real time flexibility of the tip of the transfer catheter and subsequent release of embryo(s) onto the surface of the endometrium. As a result if the embryo fails to adhere, due to some luteal phase defect or other, undefined “implantation window” problem, there is a significant risk that the embryo might be washed out of the cervix or become lodged in the fallopian tubes. In part, to compensate for this potential conceptus loss, physicians have adopted the practice of transferring higher numbers of embryos back to the uterus. Here we re-investigate the potential of surgical implantation of embryos developed to the blastocyst stage *in vitro* by day 5 or 6 post in-



semination. It does appear that this procedure may enable circumvention of those problems associated with the maternal receptivity aspect of the so called "window of implantation"(5).

Under normal, non-assisted, circumstances, implantation begins six to seven days post ovulation. It involves multiple steps which can be summarized as pre-attachment, attachment-invasion, and decidualization - early placentation (33, 34). The reader is referred to a recent paper by Dominguez et al. (3) for a comprehensive review. Thus far, mechanisms for repairing defects in this process or clinically relevant markers of uterine receptivity have proven elusive.

Similarly to the now well-accepted procedure of ICSI (35), where a single sperm is mechanically injected into an oocyte, with the development of this project we aim to develop an instrument and procedure whereby "mechanical" implantation of the embryo is achieved. Though this report only documents a very small number of patients who underwent this procedure, the data appears quite promising. A 38% clinical pregnancy rate was achieved. The year 2000 Center for Disease Control (CDC) data notes a 36% pregnancy rate (fresh embryo from nondonor) for women under 37 years of age (1). Of these clinical pregnancies, two babies were born (13%). For comparison to this study, normal miscarriage rates range between 10.6 and 16% for patients under the age of 35 (1). This rate increases to nearly 40% by 42 years of age. Clearly, a greater number of patients are needed for conclusions to be drawn on these rates when compared to those achieved with conventional ET. Notwithstanding, we reduced the number of embryos transferred in these patients, minimized the chances of "losing" the embryo, and eliminated ectopic pregnancies. Using the flexible mini-hysteroscope affords an objective and accurate confirmation of the placement of the embryo that should make the procedure replicable, and thus more reliable with more consistent and improved results.

Allowing the embryos to reach the blastocyst stage prior to transfer is gaining more acceptance (36-38). It allows both for more normal embryos to be naturally selected and for a more accurate selection of more viable, healthier embryo(s) (39-41). Thus a less number of embryos can be selected for transfer with more certainty for a successful singleton pregnancy (42, 43).

A possible drawback with the transcervical hysteroscopic embryo implantation (SEED) is the potential to scratch the endometrium and trigger

some deleterious effect. Yet this is a potential hazard of "blind" procedures as well. The risk of disruption of the uterine lining, however is postulated to be less than "blind" and ultrasound guided transfers due to the advantage of direct visualization of the uterine lining and not requiring movement of the catheter to facilitate identification during ultrasound (31). As opposed to rigid endoscopes which may cause trauma to the uterus, the hysteroscope used in this study is a mini-hysteroscope with a 3mm diameter and flexible tip that allows one to easily follow the curvature of the uterus. With this protocol, though, the physician may then choose a non-scratched portion of the endometrium for implantation. Having said that, a growing number of literature suggests that mild inflammation may very well facilitate, if not be required for implantation and placentation (44-46).

## Conclusion

Likewise, visualizing implantation allows for the physician to avoid losing embryos due to uterine contractions brought on by the transfer, enabling the physician to wait until the enhanced activity has subsided. Furthermore, visualization allows one to place the embryo at a different location if trauma ensues. Also, the catheter used is semi-rigid to prevent kinkage as it passes through the endoscope yet with enough flexibility to bend with the endoscope however bend and become kinked to prevent inadvertent passage into the myometrium. In addition, the uterine cavity is allowed to be distended during introduction of the hysteroscope into the uterus by slow passage through the endocervical canal. This would allow the hysteroscope to move in a gaseous space and not in direct contact with the endometrium as is the case with the blind procedure. In our study, no disruption to the uterine lining or uterine bleeding occurred. Increased cost is another drawback, however utilizing a hysteroscope with an objective replicable procedure that improves results will decrease the costs from multiple failed IVF-ET attempts and improve patient satisfaction. Double-blind controlled prospective studies shall be the subject of future reports, in order to investigate the full advantage and disadvantages of this technique for ET.

## Acknowledgements

This work was partially supported by Organon Pharmaceuticals, Inc. The authors are very grate-

ful to Ari Mayer Mackler, Ph.D. for advice and preparation of this manuscript. There is no conflict of interest in this article.

## References

1. Wright VC, Schieve LA, Reynolds MA, Jeng G. Assisted Reproductive Technology Surveillance - United States, 2000. *MMWR Surveillance summaries*. 2003; 52(SS09): 1-16. Available from: <http://www.cdc.gov/mmwr/preview/mmwrhtml/ss5209a1.htm>.
2. Sharkey AM, Smith SK. The endometrium as a cause of implantation failure. *Best Pract Res Clin Obstet Gynaecol*. 2003; 17(2): 289-307.
3. Dominguez F, Avila S, Cervero A, Martin J, Pellicer A, Castrillo JL, et al. A combined approach for gene discovery identifies insulin-like growth factor-binding protein-related protein 1 as a new gene implicated in human endometrial receptivity. *J Clin Endocrinol Metab*. 2003; 88: 1849-1857.
4. Jokimaa V, Oksjoki S, Kujari H, Vuorio E, Anttila L. Altered expression of genes involved in the production and degradation of endometrial extracellular matrix in patients with unexplained infertility and recurrent miscarriages. *Mol Hum Reprod*. 2002; 8: 1111-1116.
5. Kabir-Salmani M, Murphy C, Hosseini A, Valojerdi M. Ultrastructural Modifications of Human Endometrium during the Window of Implantation. *International Journal of Fertility and Sterility (IJFS)*: 2008; 2(2): 44-59.
6. Sharif K, Afnan M, Lenton W, Bilalis D, Hunjan M, Khalaf Y. Transmyometrial embryo transfer after difficult immediate mock transcervical transfer. *Fertil Steril*. 1996; 65: 1071-1074.
7. Mansour RT, Aboulghar MA, Serour GI, Amin YM. Dummy embryo transfer using methylene blue dye. *Hum Reprod*. 1994; 9: 1257-1259.
8. Biervliet FP, Lesny P, Maguiness SD, Robinson J, Killick SR. Transmyometrial embryo transfer and junctional zone contractions. *Hum Reprod*. 2002; 17: 347-350.
9. Ghazzawi IM, Al-Hasani S, Karaki R, Sousa S. Transfer technique and catheter choice influence the incidence of transcervical embryo expulsion and the outcome of IVF. *Hum Reprod*. 1999; 14: 677-682.
10. Groutz A, Lessing JB, Wolf Y, Azem F, Yovel I, Amit A. Comparison of transmyometrial and transcervical embryo transfer in patients with previously failed in vitro fertilization-embryo transfer cycles and/or cervical stenosis. *Fertil Steril*. 1997; 67: 1073-1076.
11. Nakayama T, Goto Y, Kanzaki H, Takabatake K, Himeno T, Noda Y, et al. The use of intra-endometrial embryo transfer for increasing the pregnancy rate. *Hum Reprod*. 1995; 10: 1833-1836.
12. Asaad M, Carver-Ward JA. Twin pregnancy following transmyometrial-subendometrial embryo transfer for repeated implantation failure. *Hum Reprod*. 1997; 12: 2824-2825.
13. Itskovitz-Eldor J, Filmar S, Manor D, Stein D, Lightman A, Kol S. Assisted implantation: direct intraendometrial embryo transfer. *Gynecol Obstet Invest*. 1997; 43: 73-75.
14. Wimalasundera RC, Trew G, Fisk NM. Reducing the incidence of twins and triplets. *Best Pract Res Clin Obstet Gynaecol*. 2003; 17: 309-329.
15. Pasqualini RS, Quintans CJ. Clinical practice of embryo transfer. *Reprod Biomed Online*. 2002; 4: 83-92.
16. Choe JK, Nazari A, Check JH, Summers-Chase D, Swenson K. Marked improvement in clinical pregnancy rates following in vitro fertilization-embryo transfer seen when transfer technique and catheter were changed. *Clin Exp Obstet Gynecol*. 2001; 28: 223-224.
17. Schoolcraft WB, Surrey ES, Gardner DK. Embryo transfer: techniques and variables affecting success. *Fertil Steril*. 2001; 76: 863-870.
18. Lambers MJ, Dogan E, Kosteljik H, Lens JW, Schats R, Hompes PGA. Ultrasonographic-guided embryo transfer does not enhance pregnancy rates compared with embryo transfer based on previous uterine length measurement. *Fertil Steril*. 2006; 86: 867-872.
19. Flisser E, Grifo JA. Is what we clearly see really so obvious? Ultrasonography and transcervical embryo transfer - a review. *Fertil Steril*. 2007; 87: 1-5.
20. Allahbadia G, Gandhi G, Athavale U, Merchant R, Virk SPS, Kaur K. A blind embryo transfer is a rate limiting step to successful IVF. *Fertil Steril*. 2002; 78 Suppl 1: S157-S158.
21. Puerto B, Creus M, Carmona F, Cívico S, Vanrell JA, Balasch J. Ultrasonography as a predictor of embryo implantation after in vitro fertilization: a controlled study. *Fertil Steril*. 2003; 79: 1015-1022.
22. Tiras B, Polat M, Korucuoglu U, Zeyneloglu HB, Yarali H. Impact of embryo replacement depth on in vitro fertilization and embryo transfer outcomes. *Fertil Steril*. 2009; 7: 1666.
23. Flisser E, Grifo JA, Krey LC, Noyes N. Transabdominal ultrasound - assisted embryo transfer and pregnancy outcome. *Fertil Steril*. 2006; 85: 353-357.
24. Gergely RZ, Danzer H, Surrey M, Hill D. Maximal implantation potential (MIP) pointsuggested target for optimal embryo placement within the uterine cavity during embryo transfer. *Fertil Steril*. 2007; 88(1): S328.
25. Allahbadia GN, Kadam K, Gandhi G, Arora S, Valliappan JB, Joshi A, et al. Embryo transfer using the SureView catheter-beacon in the womb. *Fertil Steril*. 2010; 93: 344-350.
26. Anderson RE, Nugent NL, Gregg AT, Nunn SL, Behr BR. Transvaginal ultrasoundguided embryo transfer improves outcome in patients with previous failed in vitro fertilization cycles. *Fertil Steril*. 2002; 77: 769-775.
27. Kol S. Ultrasound-guided embryo transfer - a special role in patients with certain uterine defects. *Fertil Steril*. 2008; 89: 260.
28. Kiltz RJ, Woodhouse D, Restive L, Miller D, Sciera A, Fundalinski J. Vaginal vs. abdominal ultrasound guidance for embryo transfer. *Fertil Steril*. 2006; 86 Suppl 1: S245-S246.
29. Gergely RZ, DeUgarte CM, Danzer H, Surrey M, Hill D, DeCherney AH. Three dimensional/four dimensional ultrasound-guided embryo transfer using the maximal implantation potential point. *Fertil Steril*. 2005; 84: 500-503.
30. Pinto AB, Wright JD, Keller SL, Odem RR, Ratts VS, William DB. Ultrasound guided embryo transfer in selected patients undergoing IVF. *Fertil Steril*. 2002; 77(3): S19.
31. Abou-Setta AM, Mansour RT, Al-Inany HG, Aboulghar MM, Aboulghar MA, Serour GI. Among women undergoing embryo transfer, is the probability of preg-

- nancy and live birth improved with ultrasound guidance over clinical touch alone? A systemic review and meta-analysis of prospective randomized trials. *Fertil Steril*. 2007; 88: 333-341.
32. Frattarelli JL, Miller KL. The pre-cycle blind mock transfer is an inaccurate predictor of anticipated embryo transfer depth. *Fertil Steril*. 2006; 86(3): S184.
33. Morrish DW, Dakour J, Li H. Life and death in the placenta: new peptides and genes regulating human syncytiotrophoblast and extravillous cytotrophoblast lineage formation and renewal. *Curr Protein Pept Sci*. 2001; 2: 245-59.
34. Giudice LC. Genes associated with embryonic attachment and implantation and the role of progesterone. *J Reprod Med*. 1999; 44: 165-71.
35. Payne D. Embryo viability associated with micro-assisted fertilization. *Baillieres Clin Obstet Gynaecol*. 1994; 8: 157-75.
36. Shapiro BS, Daneshmand ST, Garner FC, Aguirre M, Hudson C, Thomas S. High ongoing pregnancy rates after deferred transfer through bipronuclear oocyte cryopreservation and post-thaw extended culture. *Fertil Steril*. 2009; 92: 1594-1599.
37. Goto S, Kadowaki T, Hashimoto H, Kokeguchi S, Shiotani M. Stimulation of endometrium embryo transfer can improve implantation and pregnancy rates for patients undergoing assisted reproductive technology for the first time with a high-grade blastocyst. *Fertil Steril*. 2009; 92: 1264-1268.
38. Lin PY, Huang FJ, Kung FT, Wang LI, Chang SY, Lan KC. Comparison of the offspring sex ratio between fresh and vitrificationthawed blastocyst transfer. *Fertil Steril*. 2009; 92: 1764-1766.
39. Okimura T, Kuwayama M, Segawa T, Takehara Y, Kato K, Kato O. Relations between the timing of transfer, expansion size and implantation rates in frozen thawed single blastocyst transfer. *Fertil Steril*. 2009; 92(3 Suppl 1): S246.
40. Stevens J, Schoolcraft WB, Schlenker T, Wagley L, Munne S, Gardner DK. Day 3 Blastomere Biopsy Does Not Affect Subsequent Blastocyst Development or Implantation Rate. *Fertil Steril*. 2000; 74 Suppl 1: S173.
41. Weston G, Osianlis T, Catt J, Vollenhoven B. Blastocyst transfer does not cause a sexratio imbalance. *Fertil Steril*. 92: 1302-1305.
42. Stillman RJ, Richter KS, Banks NK, Graham JR. Elective single embryo transfer: A 6-year progressive implementation of 784 single blastocyst transfers and the influence of payment method on patient choice. *Fertil Steril*. 2009; 92: 1895-1906.
43. Sparks AE, Ryan GL, Sipe CS, Dokras AJ, Syrop CH, Van Voorhis BJ. Reducing the risk of multi-fetal gestation by implementation of a single blastocyst transfer policy. *Fertil Steril*. 2005; 84(Suppl 1): S86-S87.
44. Johnson GA, Burghardt RC, Bazer FW, Spencer TE. Osteopontin: roles in implantation and placentation. *Biol Reprod*. 2003; 69(5): 1458-1471.
45. Barash A, Dekel N, Fieldust S, Segal I, Schechtman E, Granot I. Local injury to the endometrium doubles the incidence of successful pregnancies in patients undergoing in vitro fertilization. *Fertil Steril*. 2003; 79: 1317-1322.
46. Wilcox AJ, Weinberg CR, O'Connor JF, Baird DD, Schlatterer JP, Canfield RE, et al. Incidence of early loss of pregnancy. *N Engl J Med*. 1988; 319: 189-194.
-