

Diagnostic Accuracy of Transvaginal Sonography in Infertile Patients with Endometrial Polyps

Maryam Niknejadi, M.D.^{1*}, Firoozeh Ahmadi, M.D.¹, Fatemeh Zafarani, B.Sc.¹, Gholamreza Khalili, M.D.², Farahnaz Ghaderi, B.Sc.¹, Zohreh Rashidi, B.Sc.¹

1. Reproductive Imaging Department, Royan Institute for Reproductive Biomedicine, ACECR, Tehran, Iran
2. Epidemiology and Reproductive Health Department, Royan Institute for Reproductive Biomedicine, ACECR, Tehran, Iran

Abstract

Background: To evaluate the diagnostic accuracy of transvaginal sonography (TVS) in infertile patients and compare its results with hysteroscopy, as the gold standard.

Materials and Methods: A total of 679 infertile women who underwent both TVS and diagnostic hysteroscopy were retrospectively investigated. TVS was performed in the mid-follicular phase (days 5-8) of their cycles. Sensitivity, specificity, and positive and negative predictive values were calculated for TVS.

Results: Hysteroscopy diagnosed endometrial polyps in 197 out of 679 cases (24.5%). TVS confirmed the hysteroscopy findings in 174 of 197 (88.3%) cases. The sensitivity, specificity, and positive and negative predictive values of TVS compared to hysteroscopy in the detection of endometrial polyps were 88.3%, 91.9%, 81.6% and 90.8%, respectively.

Conclusion: TVS is both a cost-effective and non-invasive method for the diagnosis of intra-uterine lesions such as polyps. When used in conjunction with a saline infusion, it can be a proper alternative for diagnostic hysteroscopy that saves time and enables the surgeon to perform the operative hysteroscopy procedure with greater accuracy.

Keywords: Endometrial Polyp, Diagnosis, Infertility

Introduction

The uterine cavity provides an environment for successful implantation and placentation. It is well known that structural abnormalities within the uterine cavity such as müllerian anomalies, fibroids, polyps, and synechiae play an important role in subinfertility, implantation failures and recurrent abortions (1, 2). Assessment of the uterine cavity has been performed by hysterosalpingography and hysteroscopy, but the introduction of transvaginal sonography (TVS) in the late 1980s has enabled physicians to evaluate the uterine cavity in greater detail. Recently, sonohysterography (normal saline infusion sonography) has become increasingly popular in the investigation and treatment of infertility (3, 4).

Hysteroscopy provides a three-dimensional visualization of the endometrium and is the preferred imaging study in 50%-70% of all infertility evaluations (3-7). Some studies have shown that hysteroscopy failed to diagnose uterine abnormalities which were disclosed by further diagnostic examinations such as sonohysterography and

histology (8, 9).

The goal of this retrospective study was to evaluate the diagnostic validity of TVS in the detection of uterine cavity lesions in infertile patients, when compared with hysteroscopy as the gold standard.

Materials and Methods

We performed a retrospective study of infertile women who had undergone both TVS and diagnostic hysteroscopy during the period from October 2007 to October 2008. Of 755 patients identified, 76 cases were excluded from the study and 679 patients were evaluated.

This study was performed at Royan Institute's Infertility Clinic and Reproductive Biomedicine Research Center and approved by the Royan Research Center Ethics Committee. The patients were healthy infertile women ages 20-45 with a history of primary or secondary infertility of one year or greater.

TVS was performed during the mid-follicular phase (days 5-8) of the patients' cycles (after ces-

Received: 27 Jul 2009, Accepted: 8 Dec 2009

* Corresponding Address: P.O.Box: 19395-4644, Reproductive Imaging Department, Royan Institute for Reproductive Biomedicine, Tehran, Iran

Email: mniknejadi@royaninstitute.org



Royan Institute
International Journal of Fertility and Sterility
Vol 3, No 4, Feb-Mar 2010, Pages: 157-160

sation of bleeding) and prior to diagnostic hysteroscopy in order to evaluate the size and shape of the uterus, thickness of the endometrial stripe or the endometrial echo-texture and presence of intrauterine lesions such as submucosal myomas and polyps. All sonographic examinations were done using an Aloka α -10 color doppler with a transvaginal 6 MHz probe by an expert radiologist. Polypoid lesions were considered as either round or oval localized echogenic lesions in the endometrial cavity.

Exclusion criteria were as follows: all patients with inaccurate visualization of the endometrium due to improper timing of the sonographic evaluation, a heterogenic or echogenic endometrium which resulted from either a hyperplasia or clot and cervical polyp. In cases that had normal endometrial findings on TVS, a hysteroscopy was not scheduled due to ethical considerations.

The indications for hysteroscopy were: failed *in vitro* fertilization (IVF) or failed intra uterine insemination (IUI), an observed focal localized endometrial pathology such as a polyp submucosal myoma, irregular endometrium and synechiae, or mullerian anomalies observed during hysterosalpingography or TVS.

Diagnostic hysteroscopy was performed under general anesthesia using a Storz 4mm hysteroscope (Karl. Storz, GmbH and Co. Tuttingen, Germany) by an expert gynecologist. Distention of the cavity was obtained with glycine serum. The numbers, sizes and locations of endometrial polyps were investigated. All women with clinically significant abnormalities at hysteroscopy underwent immediate operative hysteroscopy and specimens were sent for histological examination.

The sensitivity, specificity, positive and negative predictive values of TVS were calculated and compared with hysteroscopic findings, as the gold standard.

Results

Of 679 patients who underwent hysteroscopy, endometrial polyps were diagnosed in 197 (24.5%) patients.

TVS confirmed the presence of endometrial polyps in 174 out of 197 cases (88.3%), however misdiagnosed 23 cases of polyps as normal endometrium.

In 482 women, no polyps were detected during hysteroscopy. TVS was agreement with 443 (91.9%) of hysteroscopy and in 39 cases sonographic finding was suggestive of polyp (Table 1 and Table 2). Hysteroscopy was considered as gold standard.

Table 1: TVS and hysteroscopic findings of 679 patients

| TVS | Hysteroscopy | | |
|----------|--------------|----------|-------|
| | Positive | Negative | Total |
| Positive | 174 | 39 | 213 |
| Negative | 23 | 443 | 466 |
| Total | 197 | 482 | 679 |

Table 2: Diagnostic accuracy of TVS compared with hysteroscopy as the gold standard for diagnosing endometrial polyps

| Examination | Sensitivity | Specificity | PPV | NPV |
|-------------|-------------|-------------|-------|-----|
| TVS | 88.3% | 91.9% | 81.6% | 95% |

Of the 482 hysteroscopy cases who were negative for polyps, additional findings included: normal endometrium (257/482), short septum (82/482), long uterine septum (35/482), leiomyomas (24/482), intrauterine adhesions (17/482), endometrial hyperplasia (15/482), unicornuate uterus (9/482), and didelphys (2/482).

Discussion

Several studies have demonstrated that benign intrauterine lesions such as polyps, septa and leiomyomas could be causative factors for subfertility (9-10). TVS is a non-invasive modality and has diagnostic value in the evaluation of uterus and endometrial abnormalities (10-12).

The aim of the present study has been to evaluate the diagnostic accuracy of TVS when performed prior to hysteroscopy with the goal to reduce the number of diagnostic hysteroscopies that would be scheduled for infertility evaluations.

By using hysteroscopy as a gold standard, we determined that TVS had a sensitivity of 88.3%, specificity of 91.9%, positive predictive value of 81.6%, negative predictive value of 95%, and validity of 90.8% in the detection of endometrial polyps in our setting. Loverro et al. (9) and Soares et al. (13) reported that TVS had a sensitivity and specificity as high as 75-85% and 90-100%, respectively for detection of endometrial polyps.

Likewise, the positive predictive value (PPV) of TVS for detecting polyps in our setting was higher than reported by Soares et al. (13).

Of the 197 patients who were positive for endometrial polyps as determined by TVS and hysteroscopy (true positive group), 113 of these had the following pathologies: polyps (101/113), proliferative endometrium (11/113), and endometrial hyperplasia (1/113).

From 39 patients who had a positive TVS and negative hysteroscopy (false positive group),

there were 14 patients whose pathological reports were as follows: endometrial polyps (3/14) and proliferative endometrium (11/14).

The true negative group consisted of 443 patients whose findings were negative for polyps by both TVS and hysteroscopy. In this group, biopsies were done in 16 cases; all of which confirmed the absence of polyp.

There were 23 cases whose TVS results showed no endometrial polyps however they had positive findings per hysteroscopy (false negative group). Biopsies were done on 19 patients from this group, whose pathological findings were positive for either endometrial polyps (9/19) or proliferative endometrium (10/19).

Although the most accurate diagnosis is based on pathological confirmation, goal of the present study is determining agreement between transvaginal sonographic detection and direct optic visualization which has been taken during hysteroscopy.

In our study biopsies were not performed on all cases, therefore we used hysteroscopy as the gold standard for determining the presence of endometrial polyps. However, in some cases, our data showed a discrepancy between hysteroscopy and pathology results. This finding has demonstrated that hysteroscopy should not be considered as the gold standard, but it is the best method available for gynecologist. Additional complementary studies will be needed to determine hysteroscopic accuracy in comparison to pathology findings.

Although this method provides a three-dimensional, direct visualization of the uterus however its diagnostic value is dependent upon developed facilities, expert personnel and the patients' level of tolerance.

Indeed, diagnostic hysteroscopy is more invasive and less cost-effective when compared to TVS in the detection of intrauterine lesions. Moreover, this method is associated with complications such as perforations, emboli, endometritis and risks associated with anesthesia.

TVS is a noninvasive method with multiple capacities such as doppler assesment, 4D evaluation and recently saline infusion transvaginal sonography (sonohystrography) that can obviate diagnostic hystroscopy (8, 14-17) (Fig 1).

It may provide a specific diagnosis which would enable the surgeon to proceed directly to operative hysteroscopy. This method is cost-effective, less complicated and less time consuming. TVS can be a proper alternative to diagnostic hysteroscopy by saving time and enabling the

surgeon to perform the procedure more accurately (Fig 2).

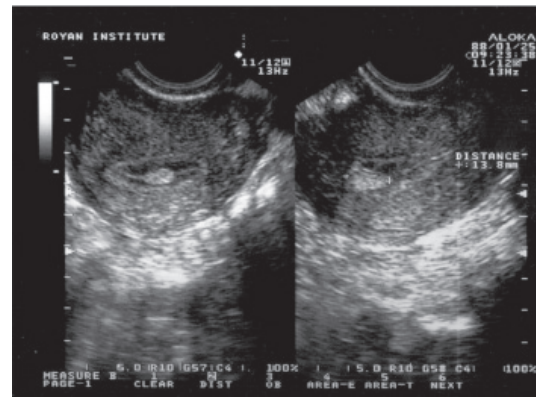


Fig 1: Transvaginal sonography of an echogenic focal lesion in the deep portion of the endometrial cavity.

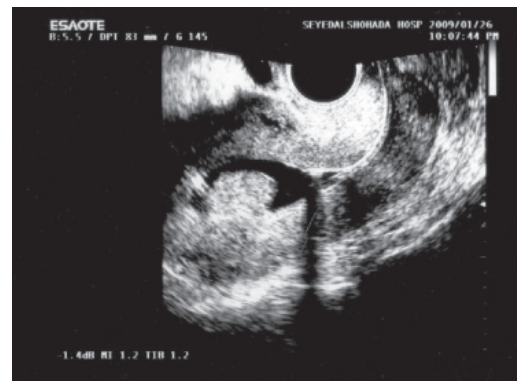

Fig 2: Hysterosalpingography shows a clearer image of a large echogenic polyp in the endometrial cavity.

Conclusion

We conclude that TVS, as a routine procedure prior to hysteroscopy, would enable physicians to detect localized endometrial lesions in greater detail.

Acknowledgements

There is no conflict of interest in this article.

References

1. Lass A, Williams G, Abusheikha N, Brinsden P. The effect of endometrial polyps on outcomes of in vitro fertilization (IVF) cycles. *J Assist Reprod Genet.* 1999; 16(8): 410-415.
2. Carlson KJ, Eisenstat SA, Ziporyn T. *The Harvard guide to women's health.* New Haven (CT): Harvard University Press; 1998; 326.
3. Parsons AK, Lense JJ. Sonohysteroscopy for endometrial abnormalities: preliminary results. *J Clin Ultrasound.* 1993; 21(2): 87-95.
4. Widrich T, Bradley LD, Mitchinson AR, Collins RL. Comparison of saline infusion sonography with office hysteroscopy for the evaluation of the endometrium.

Am J Obstet Gynecol. 1996; 174(4): 1327-1334.

5. Dicker D, Ashkenazi J, Feldberg D, Farhi J, Shalev J, Ben-Rafael Z. The value of repeat hysteroscopic evaluation in patients with failed in vitro fertilization transfer cycles. *Fertil Steril*. 1992; 58(4): 833-835.

6. Mendelson EB, Bohm-Velez M, Joseph N, Neiman HL. Endometrial abnormalities: evaluation with transvaginal sonography. *AJR Am J Roentgenol*. 1988; 150(1): 139-142.

7. Roemer T, Straube W. *Operative hysteroscopy: a practical guide*. Berlin: Walter de Gruyter; 1997: 84-89.

8. Syrop CH, Sahakian V. Transvaginal sonographic detection of endometrial polyps with fluid contrast augmentation. *Obstet Gynecol*. 1992; 79(6): 1041-1043.

9. Loverro G, Nappi L, Vicino M, Carriero C, Vimercati A, Selvaggi L. Uterine cavity assessment in infertile women: comparison of transvaginal sonography and hysteroscopy. *Eur J Obstet Gynecol Reprod Biol*. 2001; 100(1): 67-71.

10. Shalev J, Meizner I, Bar-Hava I, Dicker D, Mashiach R, Ben-Rafael Z. Predictive value of transvaginal sonography performed before routine diagnostic hysteroscopy for evaluation of infertility. *Fertil Steril*. 2000; 73(2): 412-417.

11. De Jong P, Doel F, Falconer A. Outpatient diagnostic hysteroscopy. *Br J Obstet Gynaecol*. 1990; 97(4): 299-303.

12. Granberg S, Wikland M, Karlsson B, Norström A,

Friberg LG. Endometrial thickness as measured by endovaginal ultrasonography for identifying endometrial abnormality. *Am J Obstet Gynecol*. 1991; 164(1 Pt 1): 47-52.

13. Soares SR, Barbosa dos Reis MM, Camargos AF. Diagnostic accuracy of sonohysterography, transvaginal sonography, and hysterosalpingography in patients with uterine cavity diseases. *Fertil Steril*. 2000; 73(2): 406-411.

14. Grønlund L, Hertz J, Helm P, Colov NP. Transvaginal sonohysterography and hysteroscopy in the evaluation of female infertility, habitual abortion or metrorrhagia. A comparative study. *Acta Obstet Gynecol Scand*. 1999; 78(5): 415-418.

15. Gaucherand P, Piacenza JM, Salle B, Rudigoz RC. Sonohysterography of the uterine cavity: preliminary investigations. *J Clin Ultrasound*. 1995; 23(6): 339-348.

16. Goldberg JM, Falcone T, Attaran M. Sonohysterographic evaluation of uterine abnormalities noted on hysterosalpingography. *Hum Reprod*. 1997; 12(10): 2151-2153.

17. Cepni I, Ocal P, Erkan S, Saricali FS, Akbas H, Demirkiran F, et al. Comparison of transvaginal sonography, saline infusion sonography and hysteroscopy in the evaluation of uterine cavity pathologies. *Aust N Z J Obstet Gynaecol*. 2005; 45(1): 30-35.
